

Experience of PuraStat® During Resection of a Large Circumferential, Recto-sigmoid Polyp

CASE PRESENTATION

DIAGNOSIS Carpet adenoma of rectum (Size: Circumferential lesion from dentate line to 17 cm in rectum)

PROCEDURE

- ▶ Knife Assisted snare Resection (KAR): An ESD knife was used for marking the edges of the polyp and performing circumferential mucosal incision around the lesion with some submucosal dissection before snare resecting it in multiple pieces. An electro-surgical coagulation forceps was occasionally used for hemostasis.
- ▶ PuraStat was applied, with the catheter specially designed for the syringe, a total of 4 times to the bleeding vessels in the EMR base during procedure and good hemostasis was observed. Approximately 8.5 ml of PuraStat was used in total.
- ▶ Histology: Adenoma with low grade dysplasia.

POSTOPERATIVE COURSE Repeat endoscopy at 2 weeks showed very healthy, almost healed EMR scar with mild narrowing of the lumen. Prophylactic dilatation was performed twice with no recurrence at 3 months.

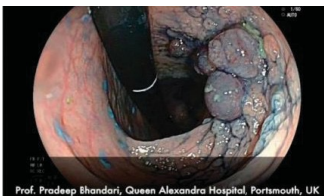

Fig. 1: Carpet adenoma of rectum

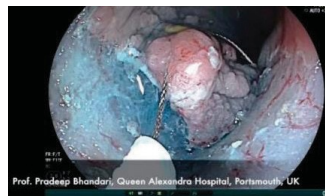


Fig. 2: Snare resection of the lesion

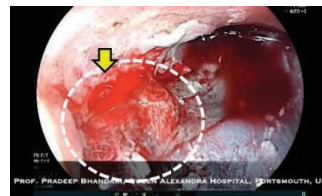


Fig. 3: White dot circle: transparent PuraStat covered the bleeding site; Yellow arrow: bleeding point

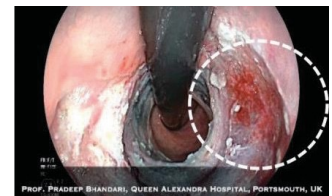

Fig. 4: Hemostasis was achieved

FEEDBACK ON PURASTAT USAGE



“PuraStat is very easy to deliver and to handle. PuraStat stops oozing and slows down brisk bleeds. It is a transparent gel which does not compromise endoscopic views after application as compared to other spray powders. This allows endoscopist to apply additional hemostatic therapy if necessary. The standard therapy for hemostasis control such as electrocautery introduces a thermal injury to the bowel wall and carries the risk of causing perforation. Furthermore, it requires precise targeting of the bleeding vessel which can be very difficult during active bleeds.”

PuraStat can be applied in the general area of bleeding and does not require precise application to the exact point of bleeding. It was really surprising to see enhanced healing and formation of soft scar at the EMR site, 15 days post procedure.”



Pradeep Bhandari, Professor
Queen Alexandra Hospital, Endoscopy Department
Portsmouth, United Kingdom



PuraStat®
Clear hemostatic control⁽¹⁾

Case Reports:
Gastrointestinal Procedures

Want to find out more about PuraStat?

Contact Us:

More information at:



PuraStat® is indicated for hemostasis of mild and moderate bleeding post ESD or EMR, as an adjunct, bridge, prophylactic or rescue therapy for intraprocedural venous bleeding or prophylactic therapy to prevent post procedure bleeding.

 **3-D Matrix North America**
1234 Chestnut Street, Suite 205
Newton, MA 02464
Tel: 855.4.3DM.MED (855.433.6633)
sales@3dmatrix.com | www.3dmatrix.com

(1) M400d-1 PuraStat IFU-003 Rev 01 09/21

Rx CAUTION: Federal law restricts this device to sale by or on the order of a physician.